

### Patient Information

<b>Age</b>	54
------------	----

### Disease information

<b>psoriasis type</b>	Psoriasis Vulgaris
<b>presence + severity</b>	Very Severe
<b>percentage Body cover</b>	All the over the body
<b>The disease exists</b>	2 Years
<b>Causes disease</b>	Unknown
<b>Genetic? Then Who has the more Family</b>	No

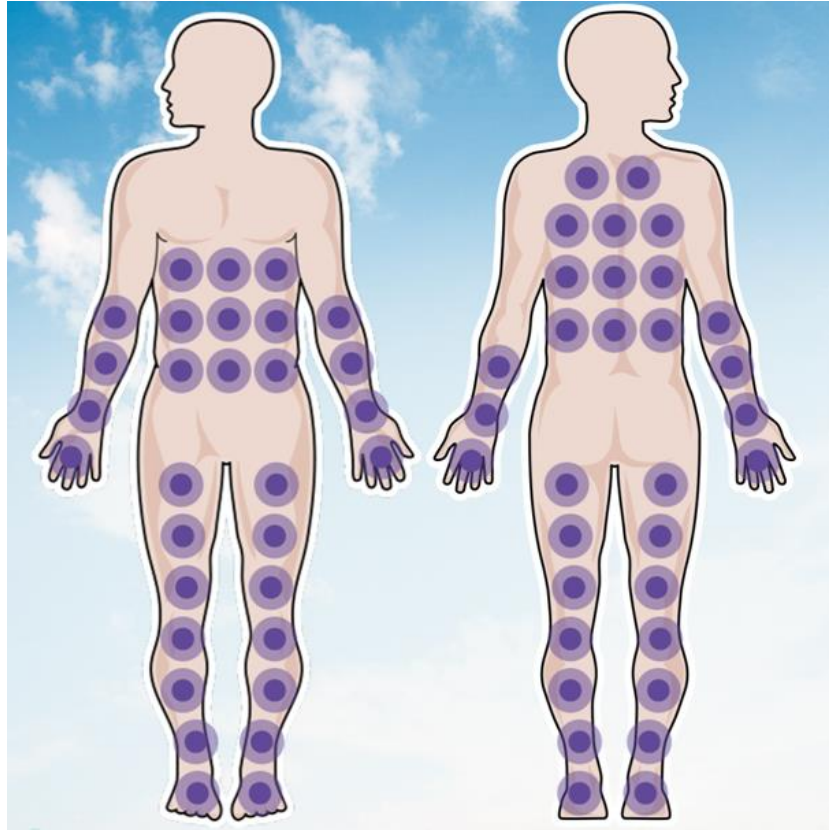
<b>Psoriasis Area</b>	<b>0 (Absent), 1 (Slight), 2 (Moderate), 3 (Severe), 4 (Very Severe)</b>
<b>Armpit</b>	Severe
<b>Arms</b>	Severe
<b>Elbows</b>	Severe
<b>Hands</b>	Severe
<b>Nails</b>	Severe
<b>Knees</b>	Severe
<b>Legs</b>	Severe
<b>feet</b>	Severe

### Proper Treatment

<b>The extent to which the patient followed treatment guideline</b>	Good
<b>Level of Use</b>	Very High
<b>General Feeling</b>	Very Good
<b>Skin Improvement</b>	Dramatic – The treatment was intense and they was a lot ointment needed.
<b>Side Effects</b>	No
<b>Continuing Care</b>	No

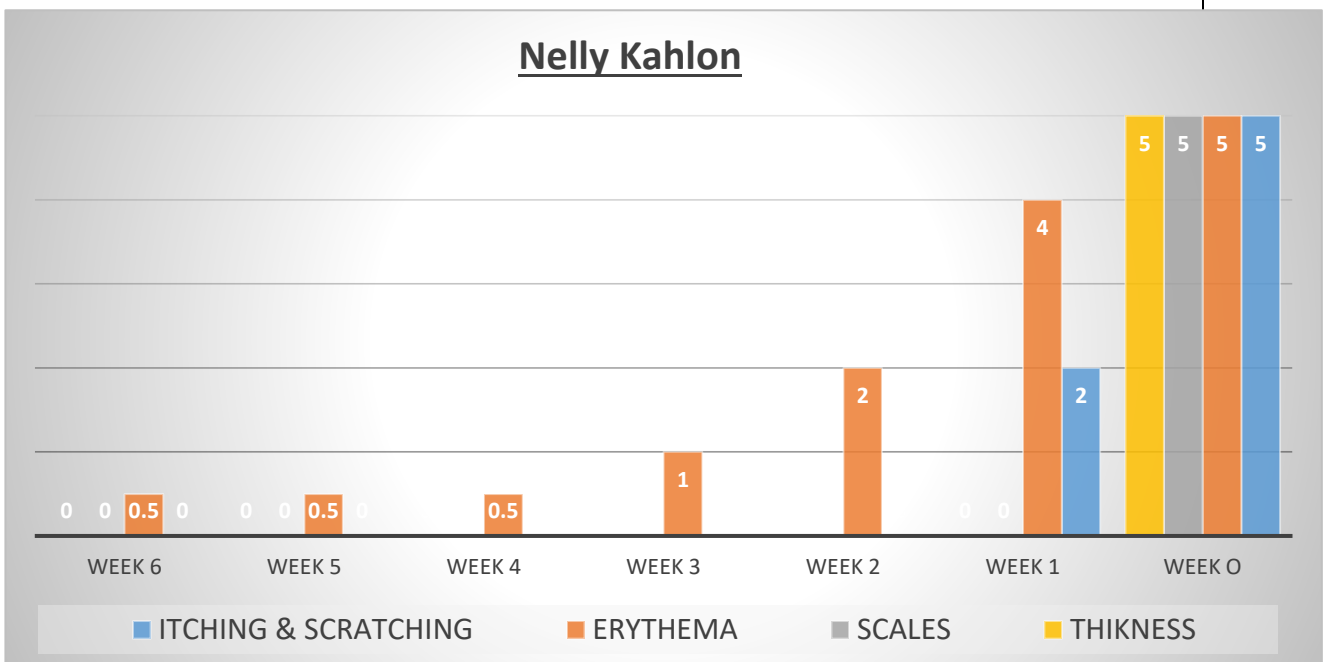
Severity

**SEVERE**



2

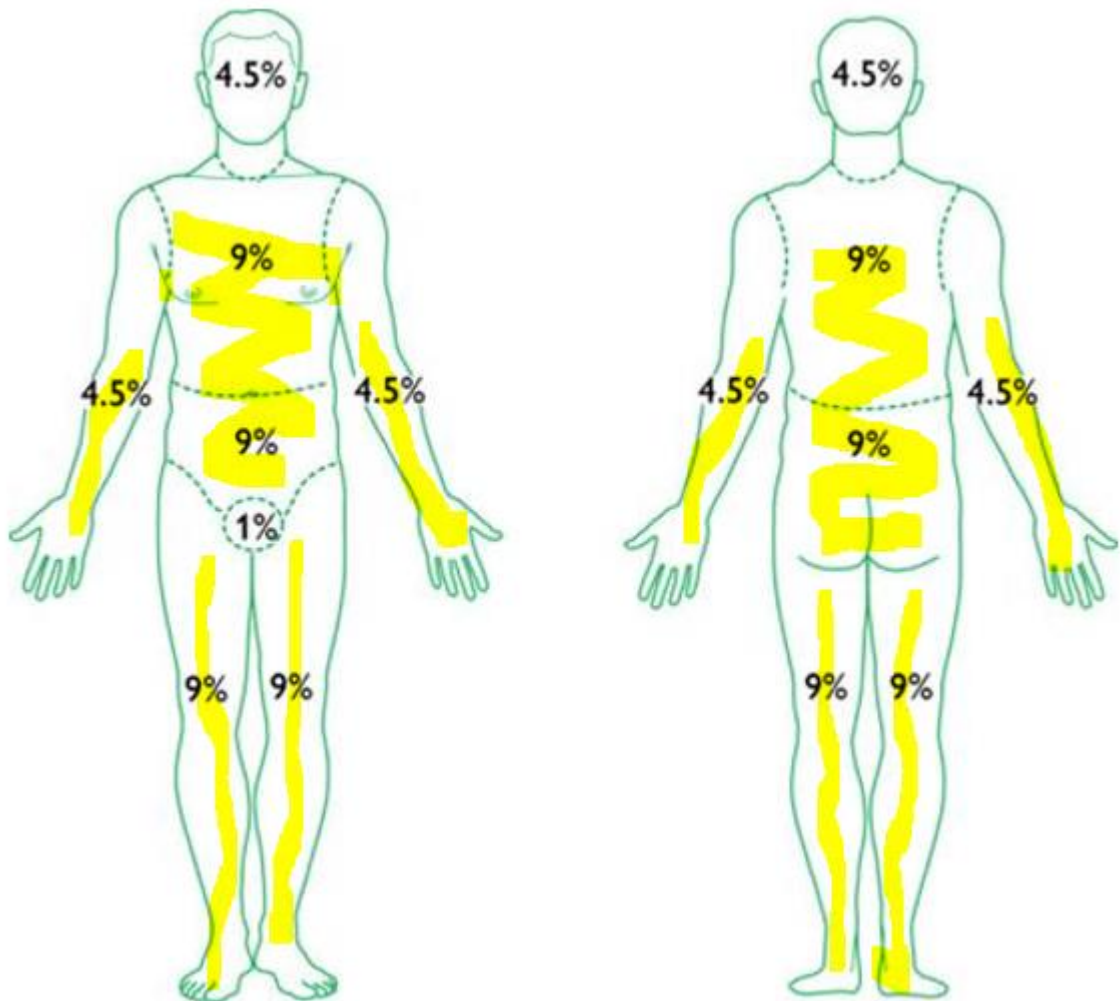
Nelly Kahlon	week 0	week 1	week 2	week 3	week 4	week 5	week 6
ITCHING & SCRATCHING	5	2	0	0	0	0	0
ERYTHEMA	5	4	2	1	0.5	0.5	0.5
SCALES	5	0	0	0	0	0	0
THICKNESS	5	0	0	0	0	0	0



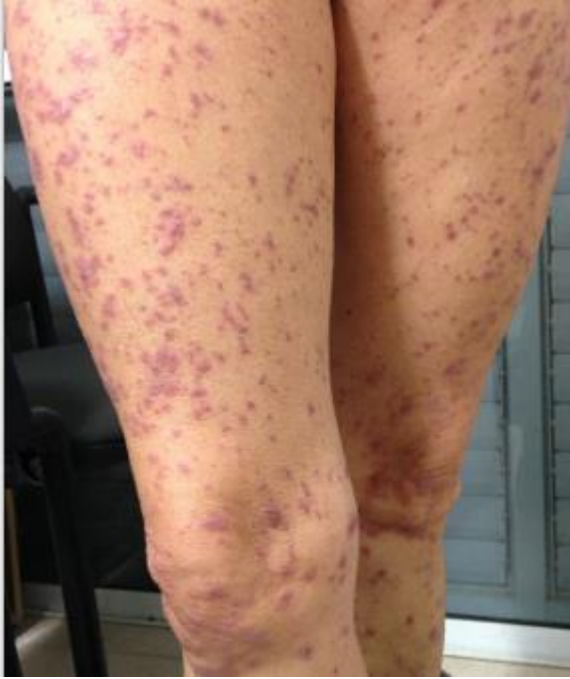The patient was suffering from a bad type of Psoriasis that was spreading all over the body. Full recovery was after a 2 months.

The last photos shows the recovered lesions that left scars.

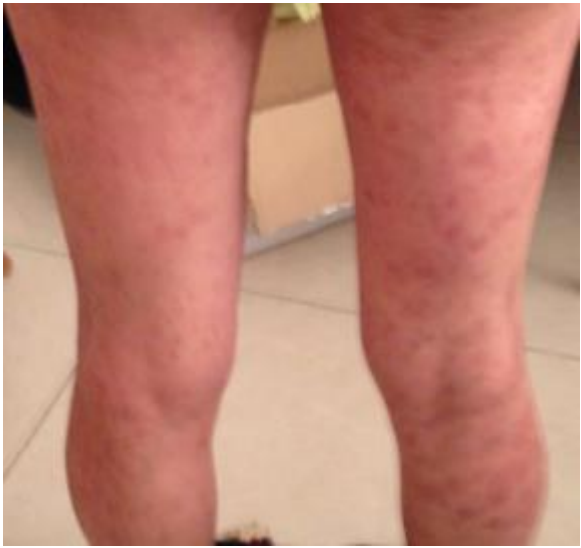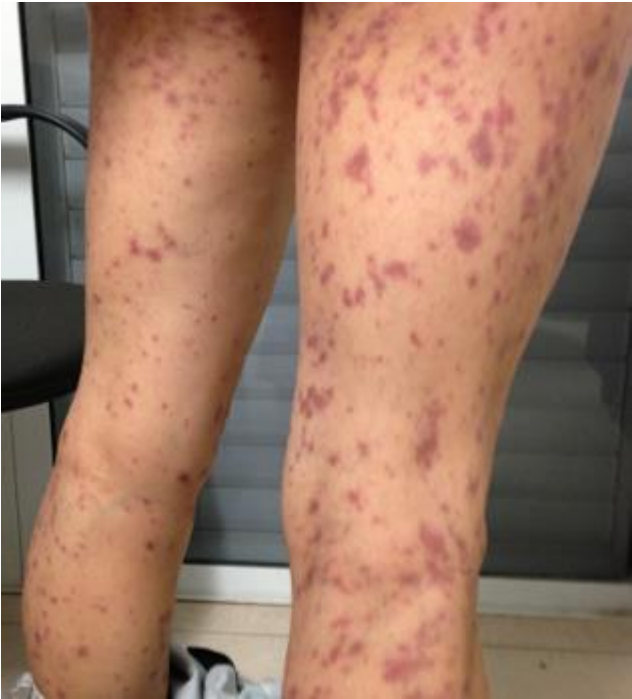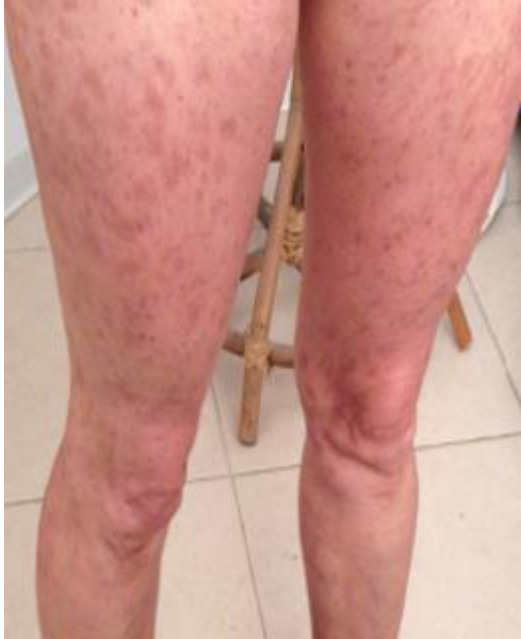The scars that remained as stains of pigmentation needed another treatment that the patient is going through these days.



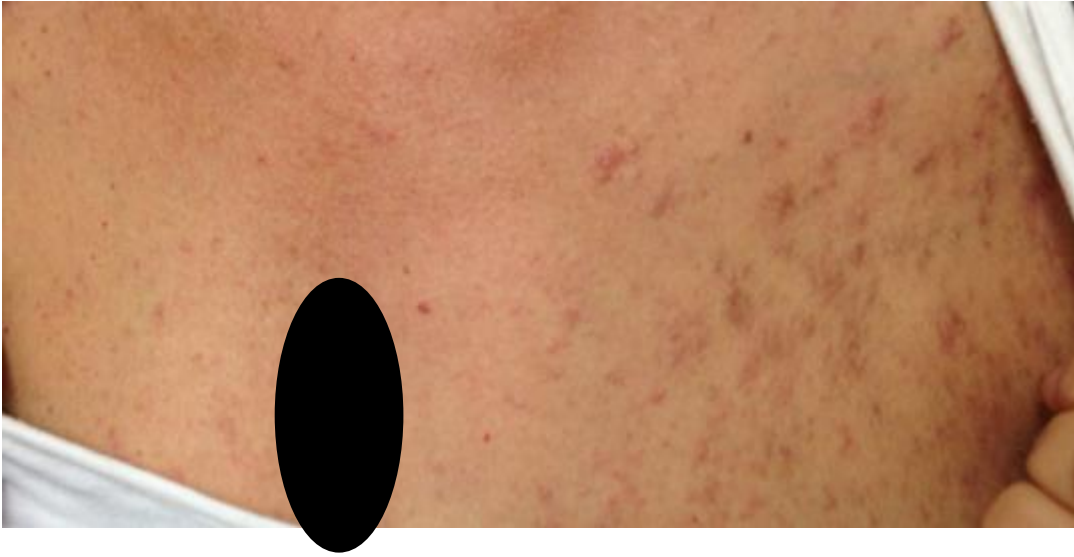Before Using DermaZor – Week 0



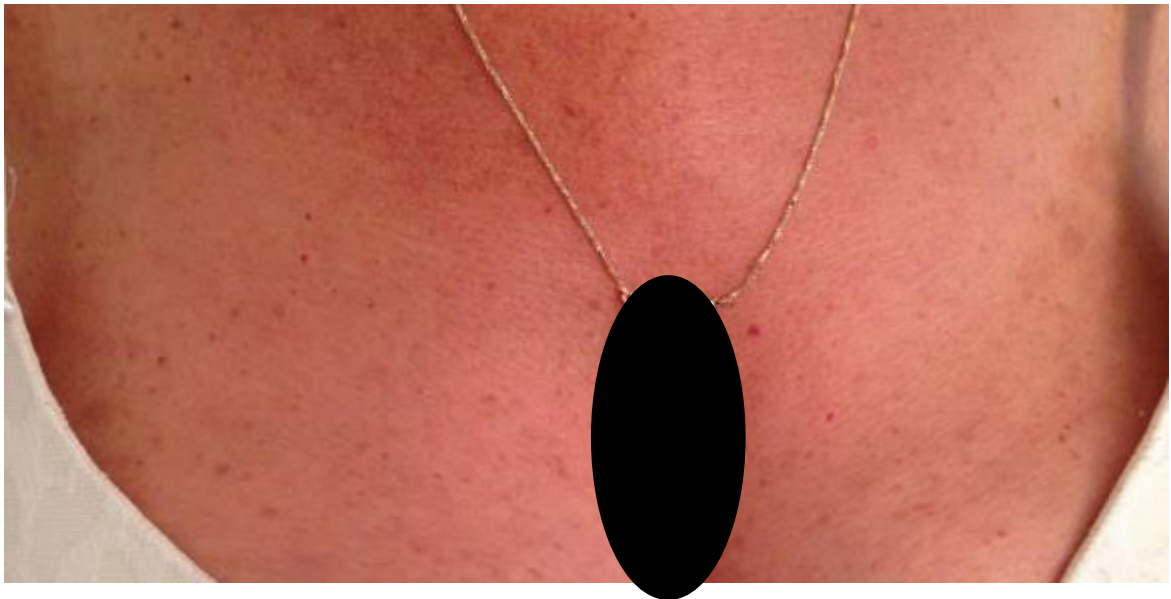After 4 weeks – Week 4



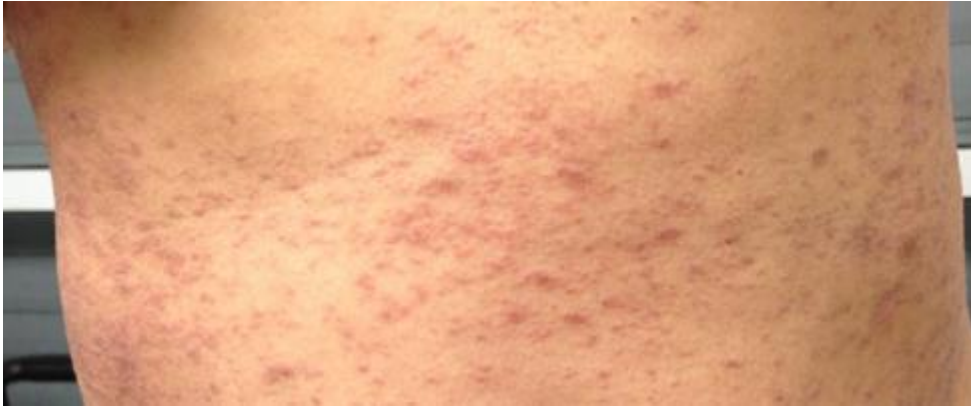Before Using DermaZor – Week 0



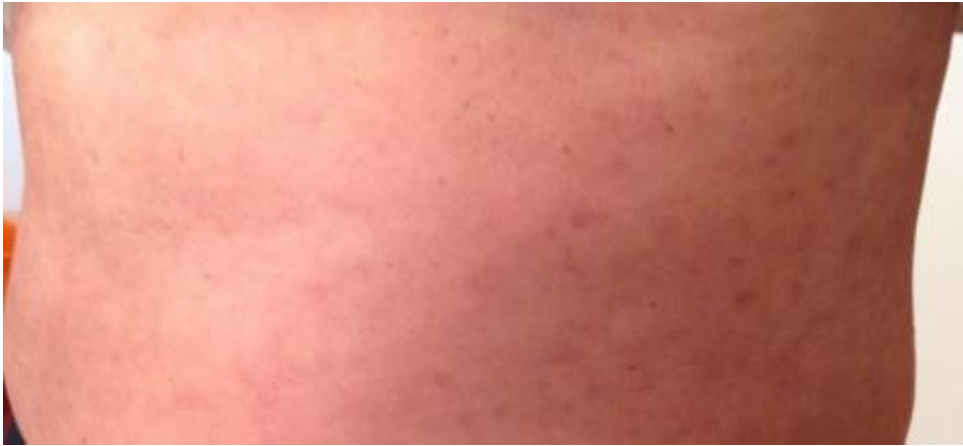After 4 weeks – Week 4



Before Using DermaZor – Week 0

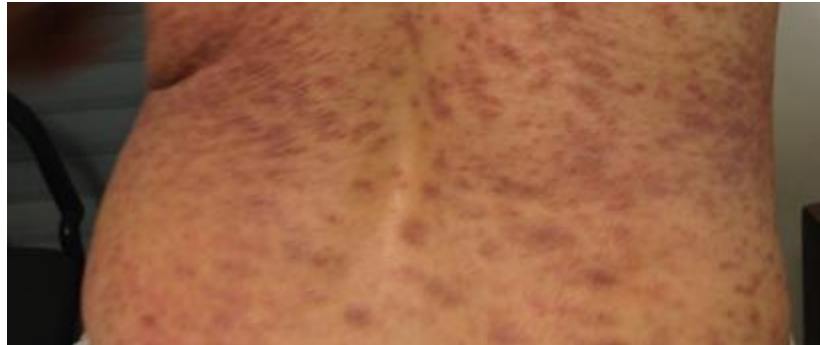

After 4 weeks – Week 4





Before Using DermaZor – Week 0



After 4 weeks – Week 4

